


Successful heart transplantation for COVID-19-associated post-infectious fulminant myocarditis

Baptiste Gaudriot^{1*} , Alexandre Mansour^{1,2}, Vincent Thibault^{2,3}, Mathieu Lederlin^{2,4}, Aurélie Cauchois⁵, Bernard Lelong⁷, James T. Ross⁶, Guillaume Laurent⁷, Jean-Marc Tadié^{2,8}, Matthieu Revest^{2,8}, Jean-Philippe Verhoye^{2,9}, Erwan Flecher^{2,9} and Nicolas Nessler^{1,10,11}

¹Department of Anesthesia and Critical Care, University Hospital of Rennes, Rennes, F-35000, France; ²Univ Rennes, CHU de Rennes, Rennes, France; ³Department of Virology, University Hospital of Rennes, Rennes, France; ⁴Department of Radiology, University Hospital of Rennes, Rennes, France; ⁵Department of Pathology, University Hospital of Rennes, Rennes, France; ⁶Department of Surgery, University of California, San Francisco, CA, USA; ⁷Department of Cardiology, University Hospital of Rennes, Rennes, France; ⁸Infectious Diseases and Intensive Care Unit, University Hospital of Rennes, Rennes, France; ⁹Thoracic and Cardiovascular Surgery, University Hospital of Rennes, University of Rennes 1, LTSI, National Institute of Health and Medical Research U1099, Rennes, France; ¹⁰Univ Rennes, CHU de Rennes, Inra, Inserm, Institut NUMECAN – UMR_A 1341, UMR_S 1241, Rennes, France; and ¹¹Univ Rennes, CHU Rennes, Inserm, CIC 1414 (Centre d'Investigation Clinique de Rennes), Rennes, France

Abstract

Various clinical presentations of the 2019 coronavirus disease (COVID-19) have been described, including post-infectious acute and fulminant myocarditis. Here, we describe the case of a young patient admitted for COVID-19-associated post-infectious fulminant myocarditis. Despite optimal pharmacologic management, haemodynamic status worsened requiring support by veno-arterial extracorporeal membrane oxygenation. Emergent heart transplantation was required at Day 11 given the absence of cardiac function improvement. The diagnosis of post-infectious COVID-19-associated myocarditis was made from both pathologic examination of the explanted heart and positive SARS-CoV-2 serology.

Keywords Fulminant myocarditis; COVID-19; Cardiogenic shock; Extracorporeal membrane oxygenation; Heart transplantation

Received: 8 February 2021; Revised: 12 March 2021; Accepted: 19 March 2021

*Correspondence to: Baptiste Gaudriot, MD, Service d'Anesthésie-Réanimation CTCV, Centre Cardio-Pneumologique, Hôpital Pontchaillou, 2 rue Henri Le Guilloux, 35033 Rennes Cedex 9, France. Email: baptiste.gaudriot@chu-rennes.fr

Introduction

Various clinical presentations of the 2019 coronavirus disease (COVID-19) have recently been described, including post-infectious acute and fulminant myocarditis.^{1–4} Here, we describe the clinical presentation and management of a young patient admitted for COVID-19-associated post-infectious fulminant myocarditis, which ultimately led to a successful heart transplantation.

Case report

A 38-year-old man presented to a primary hospital on 27 April 2020, with a 2 day history of chest pain and vomiting. Initial evaluation revealed an isolated sinus tachycardia (130 b.p.m.) without hypotension, respiratory symptoms, or fever. The electrocardiogram demonstrated an inferior and

lateral QS aspect, with incomplete right bundle branch block. Initial laboratory workup revealed an elevated C-reactive protein (60 mg/L) and high-sensitivity cardiac troponin T (1600 pg/mL > 14 pg/mL). A loading dose of aspirin and fondaparinux was administered before admission to cardiology department for suspicion of acute coronary syndrome.

The patient was native from Democratic Republic of the Congo and had been living in France for 10 years. He had no medical history, but prior laboratory testing suggested chronic lymphopaenia, which had not been worked up. He was a non-smoker. Anamnesis revealed a close contact to a COVID-19 case during a travel in Spain 5 weeks before his admission. The patient then developed fever, shortness of breath, and vomiting 4 weeks before his admission, which had resolved without treatment.

Upon admission, further workup revealed acute kidney injury (serum creatinine 130 µmol/L), a 10-fold increase in serum transaminases level, and serum ferritin at 6200 µg/L.

Troponin level increased to 2600 pg/mL with N-terminal pro-brain natriuretic peptide at 10 500 pg/mL (>300 pg/mL). Transthoracic echocardiography demonstrated a biventricular infiltrative myocardial hypertrophy, associated with a circumferential non-compressive pericardial effusion and a restrictive mitral inflow profile. There was no systolic dysfunction, and the patient's blood pressure remained stable. No coronary angiography was performed. SARS-CoV-2 reverse transcriptase polymerase chain reaction (RT-PCR) performed in nasopharyngeal swab was negative.

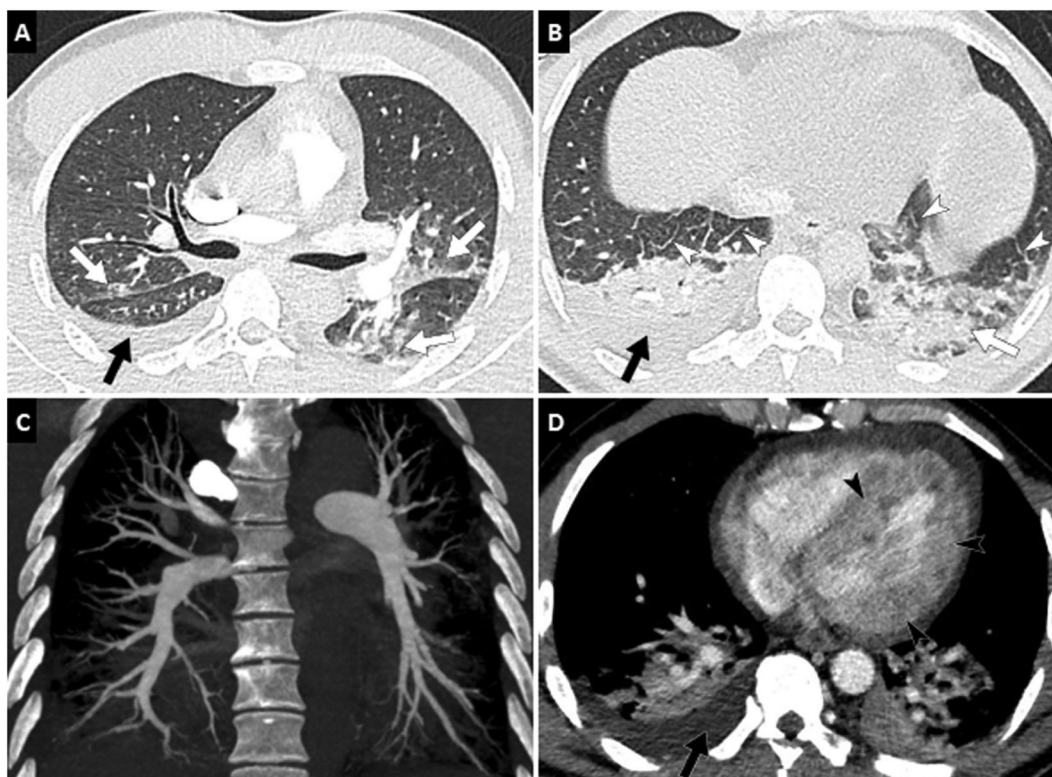
Over the first 24 h, the patient became hypotensive and hypoxaemic (nasal cannula, oxygen 4 L/min) with clinical signs of pulmonary oedema. Arterial blood gases showed moderate hypoxaemia (PO₂ 62 mmHg) and metabolic acidosis (bicarbonate 20 mmol/L) with hyperlactataemia (4.3 mmol/L). Chest computed tomography angiography (*Figure 1*) revealed a heterogeneous enhancement and thickening of the myocardium, pericardial effusion, bilateral ground glass opacities, posterior consolidations, septal lines, and a moderate right pleural effusion. No evidence of pulmonary embolism was found. A second transthoracic echocardiography demonstrated an enlarged pericardial effusion with evidence of cardiac tamponade. Emergency

pericardiocentesis with removal of 300 mL of serosanguinous exudative fluid allowed clinical and biological improvement with normalization of liver function and lactataemia.

Over the next 48 h, clinical and biological status worsened due to a rapidly progressive biventricular hypokinetic non-dilated cardiomyopathy. Left ventricular ejection fraction was 40% at Day 2 and 25% at Day 3, with major myocardial oedema and increased wall thickness. We were therefore facing a fulminant myopericarditis, with an increasing oxygen requirement and low cardiac output leading to kidney and liver dysfunction.

Cardiac magnetic resonance (CMR) imaging was performed despite patient's tachycardia and inability to hold the breath. T2 sequences showed diffuse hyperintense myocardium but suffered from too many artefacts to be considered diagnostic quality. Steady-state free precession cine images demonstrated a biventricular cardiomyopathy (left ventricular ejection fraction: 25%) with myocardial wall thickening. First-pass contrast-enhanced CMR did not reveal subendocardial perfusion defect. Late gadolinium enhancement images demonstrated massive, heterogeneous, and predominantly subepicardial enhancement of the left ventricular myocardium indicating a severe inflammation,

Figure 1 Computed tomography (CT) pulmonary angiography. (A, B) Axial CT images (lung window: W 1600/L–500 HU) show peripheral ground-glass opacities (white arrows) suggestive of COVID-19 pneumonia as well as right pleural effusion (black arrow) and septal lines (white arrowheads) related to a left ventricular dysfunction. (C) CT pulmonary angiogram in the coronal plane shows no pulmonary embolism. (D) Axial post-contrast CT image shows thickening and heterogeneous enhancement of left ventricular myocardium (black arrowheads). Note pleural and pericardial effusion.



without evidence for ischaemic heart disease (*Figure 2*, Videos S1-S2). Urine toxicology, blood alcohol, and serum thyroid stimulating hormone were all normal. Serological testing for hepatitis A, C, and E viruses, syphilis, HIV, adenovirus, and enteroviruses were all negative, while Epstein-Barr virus, cytomegalovirus, Varicella Zoster Virus, and B19 erythrovirus testing revealed former immunization. Viremia for B19 erythrovirus was negative. HBs antigen (Ag) returned positive, and the profile indicated an inactive carriage of hepatitis B virus (HBV) with low-level HBs Ag (630 IU/mL), low HBV replication (580 IU/mL), and a negative HBe Ag. Hepatitis D virus serology was negative. SARS-CoV-2 was detected neither in a second nasopharyngeal swab nor in pericardial fluid, and both isolation and personal protection equipment were withdrawn. No other respiratory virus infection tested through multiplex PCR, including influenza, para-influenza, coronaviruses 229E – HKU1 – NL63 – OC43 – MERS, adenovirus, enteroviruses, and syncytial respiratory virus, was detected. Pneumococcal and Legionella urinary antigen tests were negative.

At Day 3, despite optimal pharmacologic management, haemodynamic status worsened requiring support by veno-arterial extracorporeal membrane oxygenation (VA-ECMO) in combination with intra-aortic balloon pump and intravenous dobutamine for left ventricle venting. The patient responded well to VA-ECMO and was successfully extubated. However, left ventricular function remained profoundly altered, requiring inscription onto the list of emergent heart transplantation. After Entecavir initiation to avoid HBV replication, he underwent transplantation on 8 May (Day 11), without any previous sign of cardiac improvement. Standard immunosuppression was introduced, using antilymphocyte serum, high-dose corticosteroids (CS), and mycophenolate mofetil; maintenance used decreasing dose of CS, mycophenolate mofetil, and cyclosporine.

Pathologic evaluation of the explanted heart demonstrated pericarditis and myocarditis with large areas of myocardial necrosis, suppurated lesions, and lymphocytic infiltration (*Figure 3*). There was no SARS-CoV-2 ribonucleic acid (RNA) detected in the explanted heart. The diagnosis of

Figure 2 Cardiac magnetic resonance imaging. (A, B) Four-chamber steady-state free precession cine images at end-diastole (A) and end-systole (B) demonstrate a left ventricular dysfunction (ejection fraction: 25%) with myocardial wall thickening (17 mm), as well as bilateral pleural effusion (white arrowheads). (C, D) Four-chamber (C) and two-chamber (D) late gadolinium enhancement images show massive and heterogeneous enhancement of the left ventricular myocardium (white arrows). Note image artefacts related to patient's tachycardia and inability to hold the breath during cardiac magnetic resonance examination.

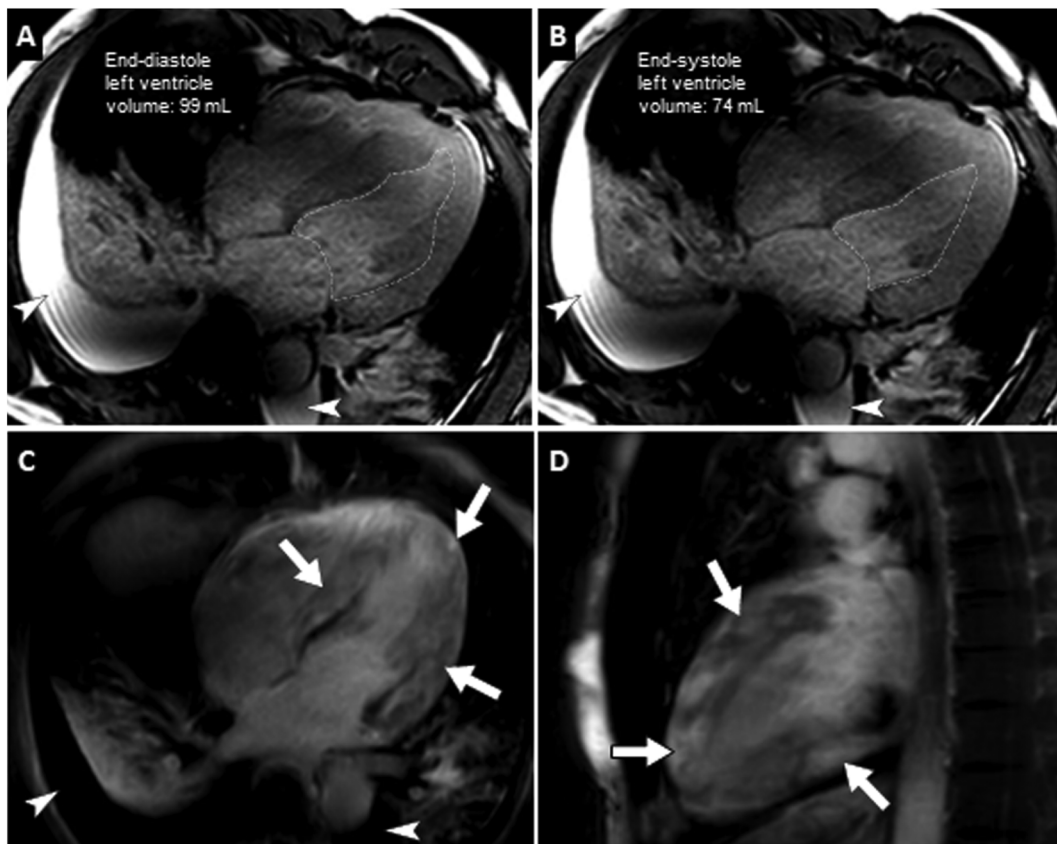
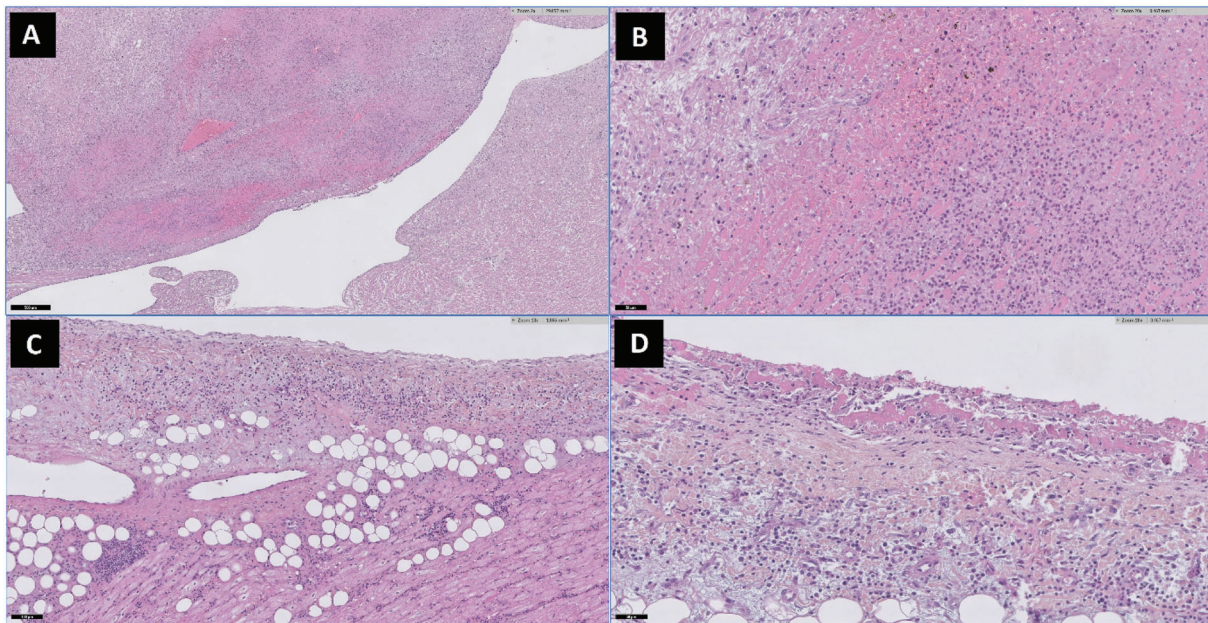


Figure 3 Pathological analysis of the explanted heart. Explanted heart was first fixed in 4% formalin solution for macroscopic examination. Multiple samples were then realized (on each ventricle, apex, septum, and coronary vessels), embedded in six paraffin blocks and stained with haematoxylin–eosin–safran before microscopic examination. Special stained were used on the more representative samples (PAS, GRAM, Grocott, Ziehl), and immunohistochemistry was also performed on 4- μ m-thick tissue sections cut and mounted on glass slides. The preparations were dried for 1 h at 58°C and overnight at 37°C. Then the tissue sections were deparaffinized with xylene, rehydrated with ethanol, and finally pretreated and immunostained using Ventana Benchmark XT® (Ventana Roche, Switzerland). *Macroscopic examination* showed focal fibrinous deposits on pericardium, no valvular or coronary abnormality after dissection, but haemorrhagic suffusions in the subendocardial area. *Microscopic examination* demonstrated a polymorphic inflammatory infiltrate, mostly in myocardium areas but focally extended to endocardium and pericardium. Lymphocytes were predominant. Infiltrate also contained plasmocytes, neutrophils, eosinophils, and histiocytic and giant cells. Clusters of neutrophils with leucocytoclasia suggested suppurated lesions. Myocardial cells were suffering with clarified cytoplasm, sometimes fibrillary or eosinophil, and with enlarged dystrophic nucleus. Large areas of necrosis and haemorrhage were seen among these inflammatory areas. Adjacent myocardium showed interstitial oedema and focally recent interstitial fibrosis. Ziehl, Grocott, Gram, and EBER ISH stains were negative. Most of lymphocytes were T phenotype CD5⁺, with only a few associated B lymphocytes CD20⁺. Numerous histiocytic cells were revealed by CD163 immunostaining. Cytomegalovirus immunostaining was negative as well as Epstein–Barr virus *in situ* hybridization. A ($\times 2$) and B ($\times 20$): necrosis and polymorph inflammatory infiltrate with haematic suffusion in endocardium and myocardium. C ($\times 10$) and D ($\times 20$): pericardial inflammatory reaction.



COVID-19 was retrospectively established by serology (Figure 4). Specific immunoglobulin M (IgM) and total antibodies were detected on the first serum sample (27 April). On follow-up sera, IgM started to decrease while total antibodies (Ab) reached a peak on 4 May.

The patient fully recovered and was discharged from the hospital for cardiovascular rehabilitation without any persistent respiratory or cardiac symptom.

Specimen collection, SARS-CoV-2 detection, and pathology

Nasopharyngeal specimens were collected according to CDC guidelines.⁵ SARS-CoV-2 real-time RT-PCR assays were performed using Allplex 2019-nCoV Assay® (Seegene, Eurobio). SARS-CoV-2 RNA detection was also performed in paraffin-embedded heart tissue.

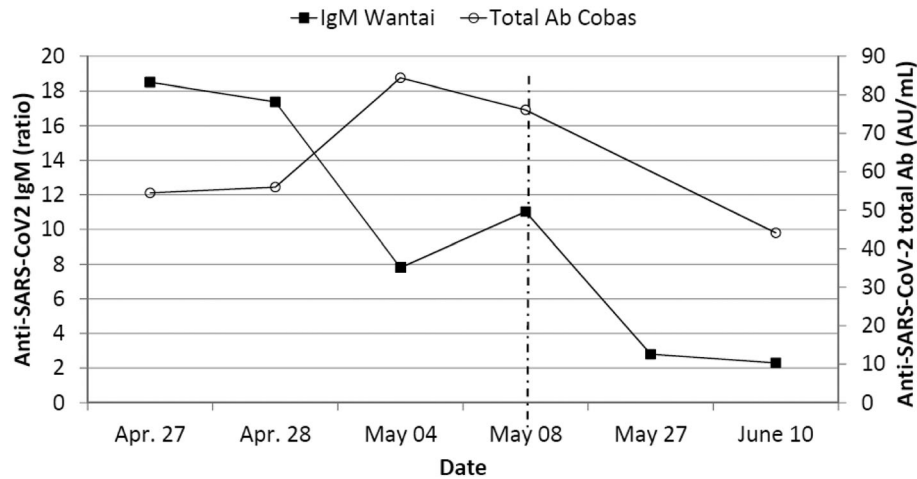
Total anti-SARS-CoV-2 antibodies detection was performed with Cobas® SARS-CoV-2 test (Roche Diagnostics), and anti-SARS-CoV-2 IgM was detected using Wantai® SARS-CoV-2 IgM ELISA (Eurobio).

Discussion

To our knowledge, we report the first case of COVID-19-associated post-infectious fulminant myocarditis successfully bridged to heart transplantation using VA-ECMO support.

Acute myocardial injury has previously been characterized as a frequent complication during COVID-19 course and is associated with morbidity and mortality.^{6–10} While pathophysiological aspects remain unclear, histologically proven COVID-19-associated myocarditis has already been reported during SARS-CoV-2 active replication states.^{11–13}

Figure 4 SARS-CoV-2 antibodies (Ab) evolution over time. Horizontal axis shows the dates of serum samples. Left vertical axis stands for anti-SARS-CoV-2-specific immunoglobulin M (IgM), represented with black squares. Right vertical axis stands for total anti-SARS-CoV-2 antibodies, represented with white circles. The vertical dashed line represents the day of heart transplantation. Serological assays following the heart transplantation should be interpreted cautiously.



Our patient met previously published echocardiographic abnormalities associated with myocardial injury in COVID-19 patients¹⁰ and CMR diagnostic criteria for myocardial inflammation.¹⁴ Despite an unstable haemodynamic status since admission, CMR has been contributive to the diagnosis, and we did not perform any endomyocardial biopsy. Typical acute lymphocytic myopericarditis was conclusively diagnosed by pathologic examination of the explanted heart.^{15,16} Aetiological diagnosis of COVID-19 was made after heart transplantation from surprising positive SARS-CoV-2 serology, performed as soon as validated assays were available in our hospital on 16 May.¹⁷ Serological profile was in favour of a recent COVID-19. SARS-CoV-2 RT-PCR remained negative in respiratory and cardiac samples. Taken together, those results are consistent with COVID-19-associated post-infectious myocarditis, as recently described by Hékimian *et al.*⁴

Veno-arterial extracorporeal membrane oxygenation support has been initially reported as a bridge to recovery for COVID-19-associated cardiogenic shock.^{4,18} Conversely, a COVID-19-associated myocarditis supported 50 days by VA-ECMO who died without myocardial recovery has been recently reported.⁴ Updated French heart allocation system only allows emergent heart transplantation up to 16 days since VA-ECMO initiation, while providing high priority during the first 12 days of VA-ECMO support.¹⁹ In this case, heart transplantation was required given the absence of clinical and echocardiographic recovery, and the final decision was made after Heart Team discussion, taking into account the preferable timing in the context of a lack of donors and grafts during the first wave of the pandemic. The patient underwent heart transplantation only 3 days before losing its national priority and ability to be transplanted. The intense immunosuppression protocol used did not result in COVID-19 rebound or in

early nosocomial infection. At the opposite, we did not try CS as a potential therapeutic option for myocarditis^{16,20,21} due to a lack of aetiological diagnosis before transplantation. Of note, most of the reported COVID-19 myocarditis have been treated by CS with favourable outcomes,²² and a preliminary report of the RECOVERY trial recently showed survival benefits in severe COVID-19 pneumonia.²³

We believe this description increases the knowledge about post-viral COVID-19-associated myocarditis and emphasizes the use of VA-ECMO support as a bridge to heart transplantation.

Acknowledgement

The authors thank Antoine Bigand for his help in reviewing the pathologic examination.

Conflict of interest

None declared.

Funding

None.

Supporting information

Additional supporting information may be found online in the Supporting Information section at the end of the article.

Video S1. Supporting Information.

Video S2. Supporting Information.

References

- Hendren NS, Drazner MH, Bozkurt B, Cooper LT. Description and proposed management of the acute COVID-19 cardiovascular syndrome. *Circulation* 2020; **141**: 1903–1914.
- Clerkin KJ, Fried JA, Raikhelkar J, Sayer G, Griffin JM, Masoumi A, Jain SS, Burkhoff D, Kumaraiah D, Rabbani L, Schwartz A, Uriel N. COVID-19 and cardiovascular disease. *Circulation* 2020; **141**: 1648–1655.
- Zheng Y-Y, Ma Y-T, Zhang J-Y, Xie X. COVID-19 and the cardiovascular system. *Nat Rev Cardiol* 2020; **17**: 259–260.
- Hékimian G, Kerneis M, Zeitouni M, Cohen-Aubart F, Chommeloux J, Bréchet N, Mathian A, Lebreton G, Schmidt M, Hié M, Silvain J, Chambrun MP, de Haroche J, Burrel S, Marot S, Luyt C-E, Leprince P, Amoura Z, Montalescot G, Redheuil A, Combes A. COVID-19 acute myocarditis and multi-system inflammatory syndrome in adult intensive and cardiac care units. *Chest* 2020. Published online ahead of print 07 September 2020.
- Centers for Disease Control and Prevention. Interim guidelines for collecting, handling, and testing clinical specimens from persons for coronavirus disease 2019 (COVID-19). 2020. Available at: <https://www.cdc.gov/coronavirus/2019-ncov/lab/guidelines-clinical-specimens.html>. Accessed 11th July 2020.
- Madjid M, Safavi-Naeini P, Solomon SD, Vardeny O. Potential effects of coronaviruses on the cardiovascular system: a review. *JAMA Cardiol* 2020; **5**: 831–840.
- Wang D, Hu B, Hu C, Zhu F, Liu X, Zhang J, Wang B, Xiang H, Cheng Z, Xiong Y, Zhao Y, Li Y, Wang X, Peng Z. Clinical characteristics of 138 hospitalized patients with 2019 novel coronavirus-infected pneumonia in Wuhan, China. *JAMA* 2020; **323**: 1061–1069.
- Doyen D, Mocerri P, Ducreux D, Dellamonica J. Myocarditis in a patient with COVID-19: a cause of raised troponin and ECG changes. *The Lancet* 2020; **395**: 1516.
- Paul J-F, Charles P, Richaud C, Caussin C, Diakov C. Myocarditis revealing COVID-19 infection in a young patient. *Eur Heart J Cardiovasc Imaging* 2020; **21**: 776–776.
- Giustino G, Croft LB, Stefanini GG, Bragato R, Silbiger JJ, Vicenzi M, Danilov T, Kukar N, Shaban N, Kini A, Camaj A, Bienstock SW, Rashed ER, Rahman K, Oates CP, Buckley S, Elbaum LS, Arkonac D, Fiter R, Singh R, Li E, Razuk V, Robinson SE, Miller M, Bier B, Donghi V, Pisaniello M, Mantovani R, Pinto G, Rota I, Baggio S, Chiarito M, Fazzari F, Cusmano I, Curzi M, Ro R, Malick W, Kamran M, Kohli-Seth R, Bassily-Marcus AM, Neibart E, Serrao G, Perk G, Mancini D, Reddy VY, Pinney SP, Dangas G, Blasi F, Sharma SK, Mehran R, Condorelli G, Stone GW, Fuster V, Lerakis S, Goldman ME. Characterization of myocardial injury in patients with COVID-19. *JACC* 2020; **76**: 2043–2055.
- Wenzel P, Kopp S, Göbel S, Jansen T, Geyer M, Hahn F, Kreitner K-F, Escher F, Schultheiss H-P, Münzel T. Evidence of SARS-CoV-2 mRNA in endomyocardial biopsies of patients with clinically suspected myocarditis tested negative for COVID-19 in nasopharyngeal swab. *Cardiovasc Res* 2020; **116**: 1661–1663.
- Tavazzi G, Pellegrini C, Maurelli M, Belliato M, Sciutti F, Bottazzi A, Sepe PA, Resasco T, Camporotondo R, Bruno R, Baldanti F, Paolucci S, Pelenghi S, Iotti GA, Mojoli F, Arbustini E. Myocardial localization of coronavirus in COVID-19 cardiogenic shock. *Eur J Heart Fail* 2020; **22**: 911–915.
- Lindner D, Fitzek A, Bräuninger H, Aleshcheva G, Edler C, Meissner K, Scherschke K, Kirchhof P, Escher F, Schultheiss H-P, Blankenberg S, Püschel K, Westermann D. Association of cardiac infection with SARS-CoV-2 in confirmed COVID-19 autopsy cases. *JAMA Cardiol* 2020. Published online 27 July 2020.
- Ferreira VM, Schulz-Menger J, Holmvang G, Kramer CM, Carbone I, Sechtem U, Kindermann I, Gutberlet M, Cooper LT, Liu P, Friedrich MG. Cardiovascular magnetic resonance in nonischemic myocardial inflammation. *JACC* 2018; **72**: 3158–3176.
- Pollack A, Kontorovich AR, Fuster V, Dec GW. Viral myocarditis—diagnosis, treatment options, and current controversies. *Nat Rev Cardiol* 2015; **12**: 670–680.
- Caforio ALP, Pankuweit S, Arbustini E, Basso C, Gimeno-Blanes J, Felix SB, Fu M, Helio T, Heymans S, Jahns R, Klingel K, Linhart A, Maisch B, McKenna W, Mogensen J, Pinto YM, Ristic A, Schultheiss H-P, Seggewiss H, Tavazzi L, Thiene G, Yilmaz A, Charron P, Elliott PM. Current state of knowledge on aetiology, diagnosis, management, and therapy of myocarditis: a position statement of the European Society of Cardiology Working Group on Myocardial and Pericardial Diseases. *Eur Heart J* 2013; **34**: 2636–2648.
- Wiersinga WJ, Rhodes A, Cheng AC, Peacock SJ, Prescott HC. Pathophysiology, transmission, diagnosis, and treatment of coronavirus disease 2019 (COVID-19): a review. *JAMA* 2020; **324**: 782–793.
- Barbaro RP, MacLaren G, Boonstra PS, Iwashyna TJ, Slutsky AS, Fan E, Bartlett RH, Tonna JE, Hyslop R, Fanning JJ, Rycus PT, Hyer SJ, Anders MM, Agerstrand CL, Hryniewicz K, Diaz R, Lorusso R, Combes A, Brodie D, for the Extracorporeal Life Support Organization. Extracorporeal membrane oxygenation support in COVID-19: an international cohort study of the Extracorporeal Life Support Organization registry. *Lancet* 2020; **396**: 1071–1078.
- Dorent R, Jasseron C, Audry B, Bayer F, Legeai C, Cantrelle C, Smits JM, Eisen H, Jacquelinet C, Leprince P, Bastien O. New French heart allocation system: comparison with Eurotransplant and US allocation systems. *Am J Transplant* 2020; **20**: 1236–1243.
- Ammirati E, Frigerio M, Adler ED, Basso C, Birnie DH, Brambatti M, Friedrich MG, Klingel K, Lehtonen J, Moslehi JJ, Pedrotti P, Rimoldi OE, Schultheiss H-P, Tschöpe C, Cooper LT, Camici PG. Management of acute myocarditis and chronic inflammatory cardiomyopathy: an expert consensus document. *Circ Heart Fail* 2020; **13**: e007405.
- Kociol RD, Cooper LT, Fang JC, Moslehi JJ, Pang PS, Sabe MA, Shah RV, Sims DB, Thiene G, Vardeny O. Recognition and initial management of fulminant myocarditis. *Circulation* 2020; **141**: e69–e92.
- Kariyanna PT, Sutarjono B, Grewal E, Singh KP, Aurora L, Smith L, Chandrakumar HP, Jayarangaiah A, Goldman SA, Salifu MO, McFarlane IM. A systematic review of COVID-19 and myocarditis. *Am J Med Case Rep* 2020; **8**: 299–305.
- The RECOVERY Collaborative Group. Dexamethasone in hospitalized patients with Covid-19—preliminary report. *N Engl J Med* 2020. Published online 17 July 2020.